




ELSEVIER

Contents lists available at ScienceDirect

Best Practice & Research Clinical Anaesthesiology

journal homepage: www.elsevier.com/locate/bean



7

Ultrasound-guided ankle block. History revisited



Alain Delbos, MD, Consultant Anesthetist ^{a, *},
Marty Philippe, MD, Consultant Anesthetist ^a,
Chassery Clément, MD, Consultant Anesthetist ^a,
Rontes Olivier, MD, Consultant Anesthetist ^a,
Steve Coppens, MD, Consultant Anesthetist ^b

^a Medipole Garonne, Toulouse, France

^b Department of Anaesthesiology, University Hospitals of the KU Leuven, Herestraat 49, 3000, Leuven, Belgium

Keywords:

Foot surgery
Ankle blocks
Tibial nerve block
Peroneal nerve block
Sural nerve block
Saphenous nerve block
Regional anesthesia

A B S T R A C T

Following forefoot surgery, compared to the traditional multimodal approach, regional anesthesia and analgesia provides high quality pain relief, decreases opioids consumption and leads to very high satisfaction scores. Traditional regional techniques relied either on wound infiltration, landmark technique ankle blocks or popliteal sciatic nerve block. Numerous anatomic variations of the different nerves might lead to failure following a blind technique. The current evolution towards ambulatory care will push surgical teams to favor techniques that simplify postoperative treatment and encourages immediate ambulation.

The development of Ultrasound Guided Blocks has enabled us to perform very selective and precise nerve blocks.

Ankle blocks provide excellent intraoperative anesthesia as well as long postoperative pain relief. Complications are rare using regional anesthesia for postoperative analgesia even after extensive foot surgery.

Revival of ankle blocks is a perfect example of the high impact of new technological advances in improving ambulatory surgical care after foot surgery.

© 2019 Elsevier Ltd. All rights reserved.

* Corresponding author.

E-mail address: alaindelbos@wanadoo.fr (A. Delbos).

Foot surgery is characterized by intense postoperative pain, difficult to control even when using balanced multimodal analgesia associating paracetamol, anti-inflammatory drugs, and opioids [1]. Acute postoperative pain lasts significantly longer than 24 h [2].

Following forefoot surgery, 80% of patients experience severe pain and 32% suffer from nausea in the postoperative period [3]. Most of the patients require high doses of postoperative opioids for pain relief after foot and ankle surgery [4]. Compared to the traditional multimodal approach, regional anesthesia and analgesia provides high-quality pain relief, decreases opioids consumption, and leads to very high satisfaction scores [3,5].

Traditional regional techniques relied on wound infiltration, landmark technique ankle blocks, or popliteal sciatic nerve block. Even though Rudkin et al. reported a high success rate using landmark technique ankle blocks, numerous anatomic variations of the different nerves might lead to failure following a blind technique [6]. With the introduction of the ultrasound-guided blocks, most practitioners opted to use popliteal block, with or without catheter techniques. Ankle blocks were all but abandoned.

Since the implementation of enhanced recovery programs and fast-track orthopedic surgery protocols, there has been a renewed interest in ankle blocks [7]. Quick mobilization and resumption of daily activity are extremely important for postoperative care, especially for metatarsal osteotomies. Under these conditions, the main challenge of the anesthesia team is to achieve a simple, reliable, and prolonged analgesia allowing swift ambulatory discharge.

In skilled hands, an ultrasound-guided ankle block will provide safer and even quicker analgesia and anesthesia while allowing fast mobilization and rehabilitation. When compared to landmark technique, the ultrasound-guided ankle block increases success rates, reduces the conversion rate to general anesthesia (GA), and decreases postoperative analgesic requirements [5].

Complications are rare using regional anesthesia for postoperative analgesia even after extensive foot surgery; however, the consequences of motor or sensory deficits can be extremely devastating, as it impacts mobility [8,9].

Anatomic basics for regional anesthesia

Foot innervation is provided both by the sciatic nerve and by the saphenous nerve (which is the terminal sensory branch of the femoral nerve).

The sciatic nerve divides into 2 terminal branches: the common peroneal nerve and the tibial nerve. The sural nerve branches off the tibial nerve, but some neural connections with common peroneal nerve are frequent at the level of popliteal fossa. It is a pure sensory nerve.

Finally, the common peroneal nerve divides into 2 terminal branches: the deep peroneal nerve and the superficial peroneal nerve.

All these five terminal branches (saphenous, tibial, superficial peroneal nerve, deep peroneal nerve, and sural nerve) cover foot innervation (Fig. 1).

The saphenous nerve supplies skin innervation over the medial part of the ankle and foot, up to the head of the first metatarsal [10]. Skin innervation may have an extension toward the first toe with an average of 6.5 cm from the medial malleolus but may in some cases exceed 9 cm [11].

The **sciatic nerve**, with its 4 terminal branches, provides innervation of the remaining parts of the foot.

The tibial nerve innervates all the plantar face (bone and teguments) of the foot, as well as the dorsal side of the first phalanx of the 1st, 2nd, and half of the 3rd toe [10].

The deep peroneal nerve innervates bones of the dorsal side of the foot and a limited cutaneous area between the 1st and the 2nd toe.

The superficial peroneal nerve innervates a large part of the skin of the dorsal side of the foot.

The sural nerve innervates the external malleolus and the dorsal side of the 5th and the 4th toe, running frequently until the 3rd toe [12] [Fig. 2].

Sciatic nerve block

This block remains the technique of reference. It provides anesthesia for the entire foot [13], when combined with a saphenous nerve block.

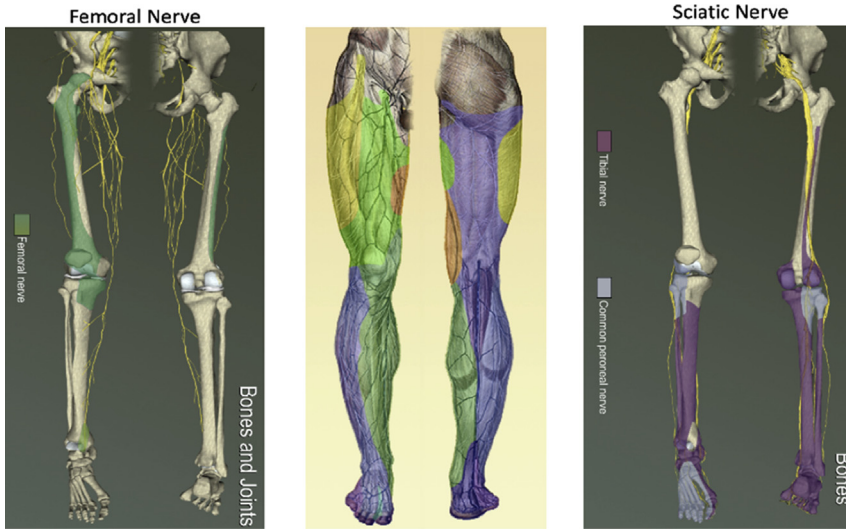


Fig. 1. Lower extremity nerves: sensory distribution.

The common puncture site for foot surgery is located at the popliteal fossa. Ultrasound guidance at this level is easily performed using a 10–12 MHz linear probe [14]. Combination with a nerve stimulator technique is possible.

The UltraSound Guided Block (USGB) technique allows to visualize the sciatic nerve and the adjacent vascular structures (popliteal artery and vein) to detect the anatomical variations (level of separation of the tibial nerve and the common peroneal nerve). It allows locating precisely the paraneurium, the last fascia surrounding the sciatic nerve, which delimits the subparaneural space [15,16] where injection of local anesthetics (LA) provides a higher success rate, longer analgesia duration, and a shorter onset time [17].

The sciatic nerve block is followed by a motor block of the flexor muscles of the foot (peroneus longus and brevis muscles, flexor hallucis longus, and triceps sural muscle innervated by the superficial peroneal and tibial nerves) and extensor muscles of the foot (extensor digitorum longus, anterior tibial muscle, and extensor hallucis longus innervated by deep peroneal nerve).

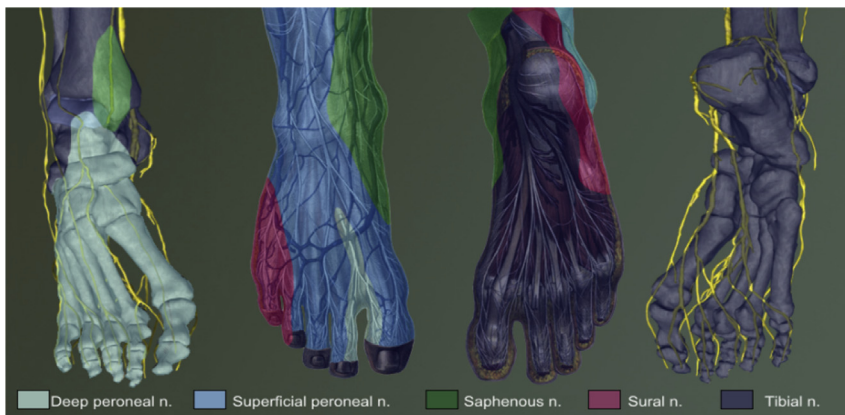


Fig. 2. Nerves of the foot, sensory distribution.

This motor block induces motor weakness of the knee as well as a foot drop, which increases the risk of ankle sprain and chances on inpatient falls. Inability to walk without support can prolong length of stay or impede quick ambulation.

Ankle block

This technique blocks the terminal branches of the sciatic nerve and the terminal branch of the femoral nerve (the saphenous nerve at this level).

Two nerves that innervate bony structures of the foot are therefore mandatory for surgery and postoperative pain management. These are the deep peroneal nerve for the dorsal side of the foot, and the tibial nerve for the plantar side. The skin, tendons, and muscles are innervated by all four branches of the sciatic nerve. The ankle block, described for many years according to a “landmark technique,” had a limited interest owing to a high failure rate of more than 30% [18]. Moreover, these blind superficial infiltrations were very painful for the patient due to the need for high volumes of local anesthetics. The USGB makes this block safe and effective. It requires the use of a high-frequency linear probe (14–18 MHz) suitable for such superficial blocks.

Tibial nerve

Landmark technique

The needle is inserted between medial malleolus and Achilles tendon, where the tibial nerve runs posterior to the palpated tibial artery. It is technically difficult and not reliable without eliciting paresthesia. Moreover, the tibial artery is not always readily palpable [19]. The tibial nerve usually lies posterior to the tibial artery but could also run anterior to the artery explaining the difficulty to block the nerve using landmark technique even if different techniques and puncture sites have been described.

Nerve stimulation technique

The puncture site is situated at the antero-medial border of the Achilles tendon, 4–5 cm above the medial malleolus, just posterior to the tibial artery (Fig. 3). The needle is advanced until a typical motor response is elicited: flexion of the toes [10].

Compared to the landmark technique, nerve stimulation technique improves the success rate of tibial nerve block [20] but still has an increased risk of accidental vascular puncture.

USGB

The probe is placed transversally across the medial aspect of the lower leg, just above the medial malleolus [Fig. 4]. The needle is inserted posterior to the probe in the direction of the tibial nerve,

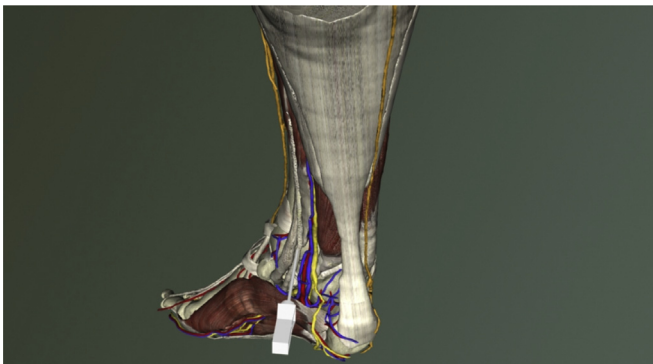


Fig. 3. Nerve stimulation tibial nerve block.

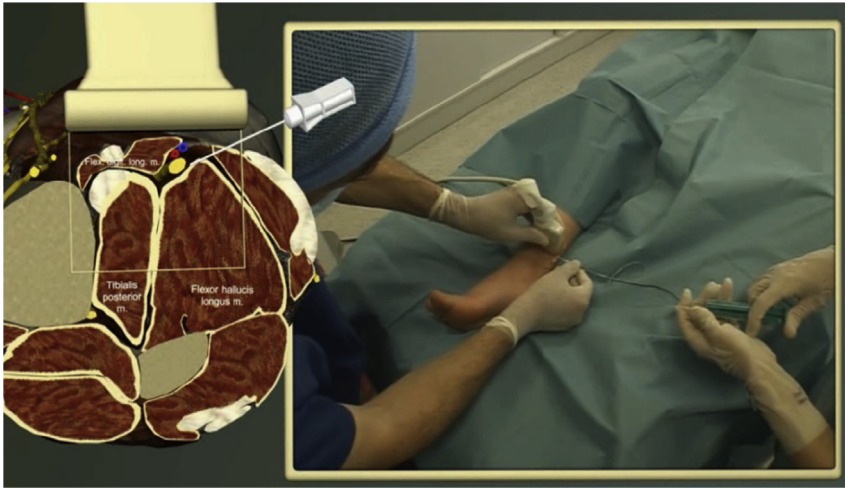


Fig. 4. USGB tibial nerve block needle insertion.

which usually lies directly behind the tibial artery. The tibial nerve requires a total of at least 5–7 ml of local anesthetic to be sufficiently blocked [Fig. 5].

Moreover, USGB technique, when performed very distally behind the medial malleolus, is able to selectively block the plantar nerve while sparing the calcaneal branch, which emerges a few centimeters more proximally. This selective distal block anesthetizes the forefoot while avoiding anesthesia of the calcaneum, thereby facilitating early postoperative walking.

Deep peroneal nerve

Landmark technique

The puncture site is situated between the extensor hallucis longus tendon medially and extensor digitorum longus laterally at the lateral border of the palpated anterior tibial artery. The deep peroneal nerve requires approximately 5 ml of local anesthetic to provide adequate block [21] (Fig. 6).

USGB

The probe is placed at the anterior ankle joint on the anterior aspect of the tibia.

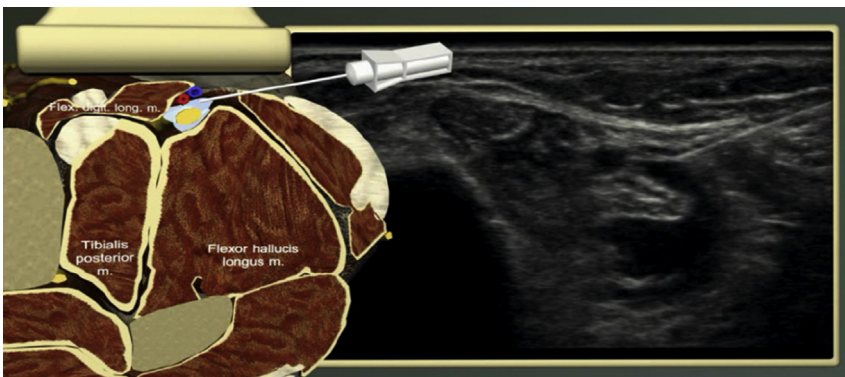


Fig. 5. USGB tibial nerve block technique.

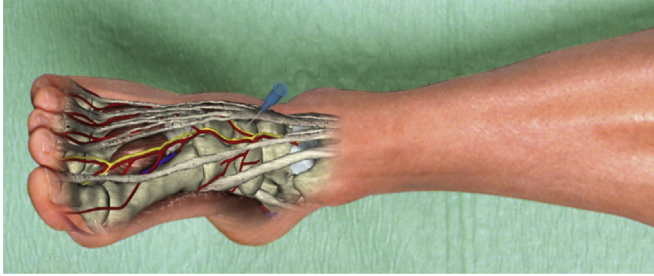


Fig. 6. Deep peroneal nerve block landmark technique.

The puncture site is located at the lateral end of the probe in the in-plane technique or caudal of the long axis of the probe in the out-of-plane technique (Fig. 7).

The deep peroneal nerve is usually lateral to the anterior tibial artery, lying on the anterior face of the tibia. The needle is placed toward the deep peroneal nerve, and 4–6 ml of local anesthetic is injected. If the nerve is difficult to identify, a perivascular injection can be used (Fig. 8). Nerve

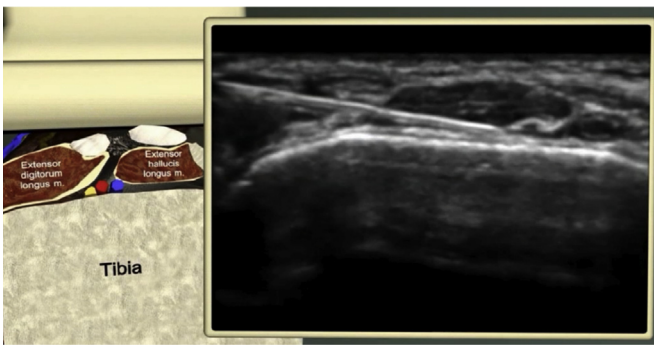


Fig. 7. USGB Deep peroneal nerve block needle insertion.

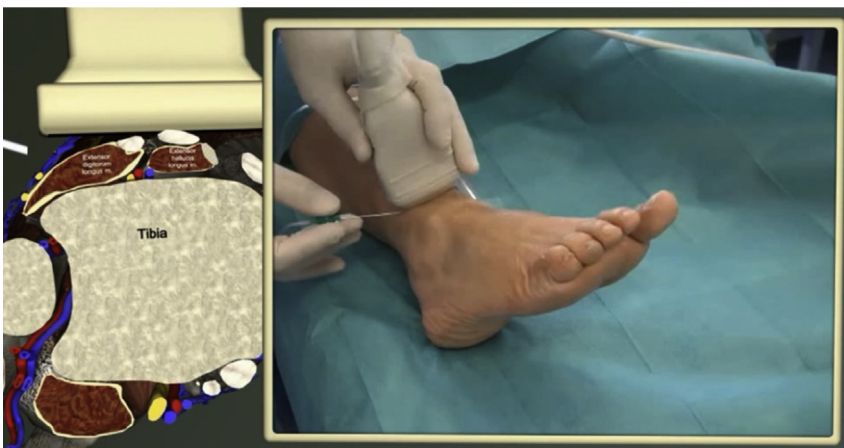

Fig. 8. USGB deep peroneal nerve block technique.

stimulation technique can be also used in addition to ultrasound to confirm the needle position with a typical motor response from toes [22].

Antonakis et al. found that compared to a conventional landmark technique, the use of ultrasound did not improve the overall quality of the deep peroneal nerve at the ankle level [21]. However we believe that ultrasound use is genuinely helpful because the anterior tibial artery is not always readily palpable [23]. In addition, in described anatomic variations, the anterior tibial artery and the deep peroneal nerve were visualized 1–1.5 cm lateral to the extensor hallucis longus tendon explaining potential failure with landmark techniques [22].

These anatomic variations and the level of division of the nerve in medial and lateral branches could also explain the difficulty to consistently block this nerve with the landmark technique [18]. An injection on both sides of the artery could prove to be more effective but may lead to higher chances of accidental vascular punctures.

The main advantage of ultrasound is to visualize both nerve and anterior tibial artery. This explains why most practitioners prefer to use the USGB technique when blocking the deep peroneal nerve.

Superficial peroneal nerve

Landmark technique

This block is performed 2–4 cm above the lateral malleolus with a 3–5 ml semicircular subcutaneous infiltration from the tibial crest to the fibula. At this level, the nerve has emerged either subcutaneously or deep into the fascia, which may explain a high failure rate using landmark techniques. In an anatomical study, in 20.1% of specimens, the superficial peroneal nerve branched before piercing the deep fascia [24] (Fig. 9).

USGB

Probe is positioned on the lateral aspect of the lower leg just proximal to the fibula (Fig. 10). The superficial peroneal nerve can be identified between the extensor digitorum longus and peroneus brevis muscles (Fig. 11).

It pierces the fascia in the lower third of the leg to become more superficial. Bowness et al. demonstrated that the nerve was found to transfix the deep fascia of the leg just anterior to a point 30–31% along a straight line from the lateral malleolus to the head of the fibula [25].

The nerve can be blocked with 4–6 ml of local anesthetic either beneath the fascia or just after it has punctured the fascia. It is important to block this nerve as proximal as possible before its distal division.

With USGB, the same approach as the landmark technique is used but adding a clear view of the nerve above or under the deep fascia. Several different terminal branches should be easily identifiable, piercing the deep fascia proximally in diverse locations.

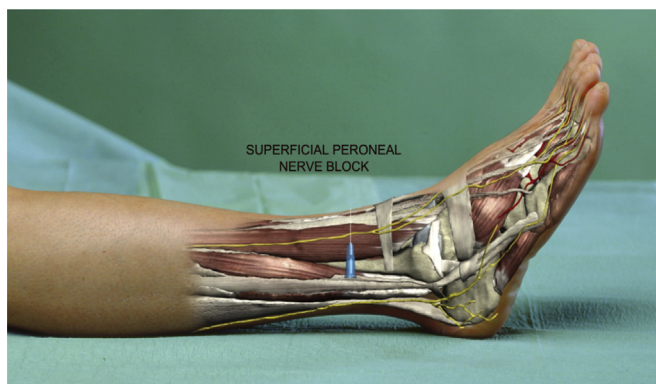


Fig. 9. Superficial peroneal nerve block landmark technique.

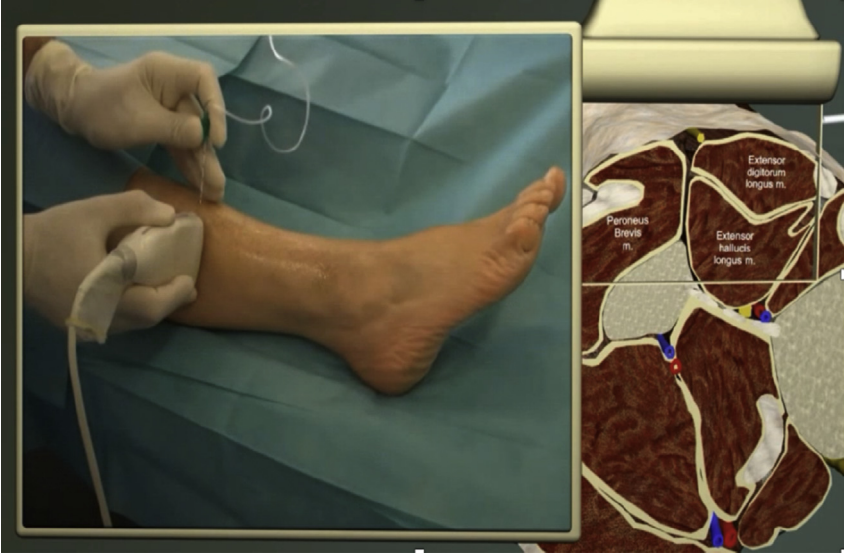

Fig. 10. USGB superficial peroneal nerve block needle insertion.

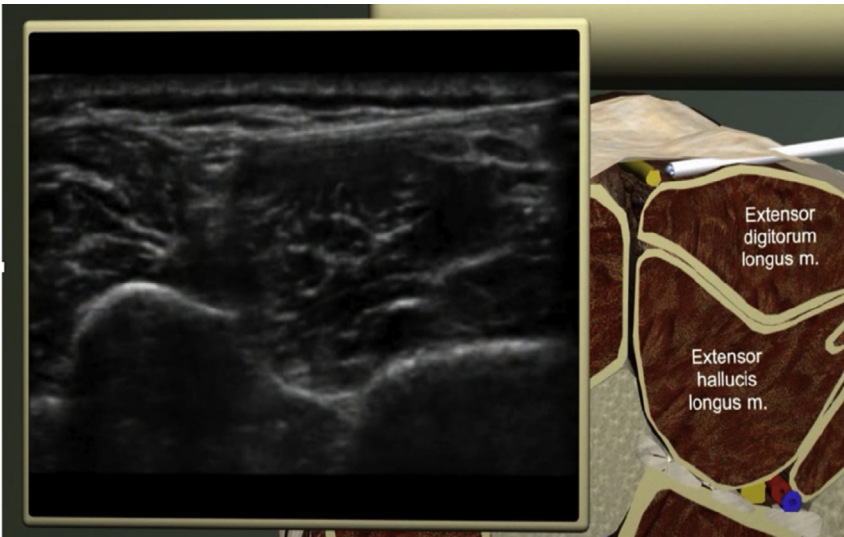


Fig. 11. USGB superficial peroneal nerve block technique.

Sural nerve

Landmark technique

This block is performed 2–4 cm above and posterior to the lateral malleolus with a 3–5 ml semicircular subcutaneous infiltration from the fibula to the Achilles tendon (Fig. 12).

The sural nerve is known to be extremely superficial (at 0.5 cm to the skin surface); however, the landmark technique is not as reliable as USGB. In fact, using the short saphenous vein as a reference point on ultrasound has a much higher success rate in blocking the sural nerve [25].

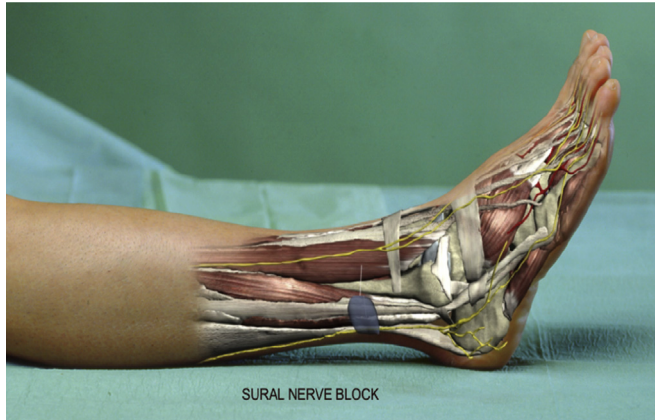

Fig. 12. Sural nerve block landmark technique.

USGB

The probe is positioned on the posterolateral aspect of the leg, just proximal to the lateral malleolus (Fig. 13). As previously mentioned, using ultrasound to scan and pinpoint the short saphenous vein very superficially is a very effective approach to the sural nerve. The sural nerve is often visible close to the vein on the lateral aspect of the lower leg just proximal to the medial malleolus. The short saphenous vein is identified, lying superficially between the Achilles tendon and the peroneus brevis muscle. The sural nerve is enveloped in a perivascular sheath. If the nerve is not identifiable, perivascular local anesthetic injection on both sides of the short saphenous vein can be used to produce adequate block (Fig. 14).

The sural nerve has a variable innervation distribution that can involve the third digit and the plantar medial border of the heel [12]. With regard to this, the block is not mandatory for surgery of the first and the second toe even if a deep sensory nerve block of the lateral foot and ankle is often more comfortable for patients.

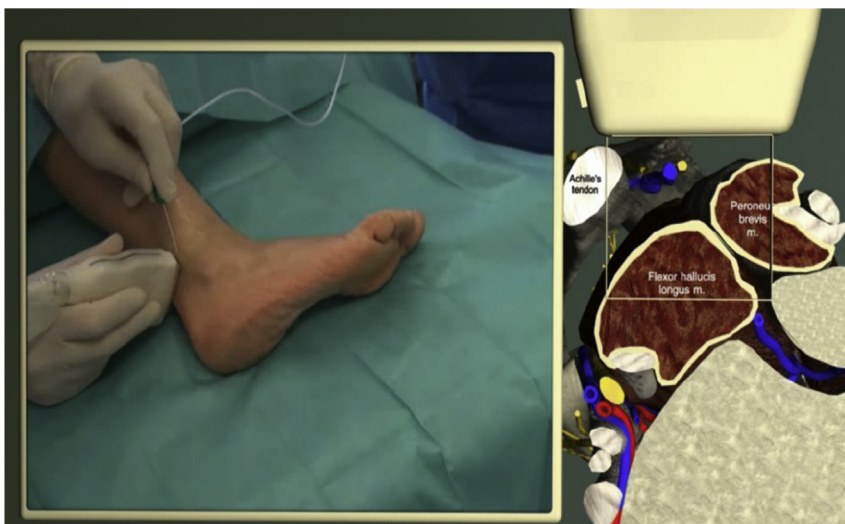

Fig. 13. USGB sural nerve block needle insertion.

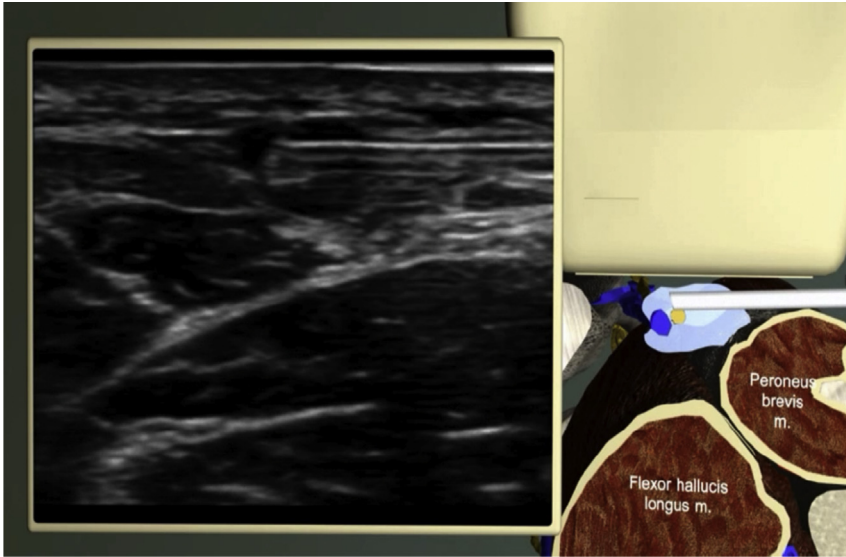


Fig. 14. USGB sural nerve block technique.

Saphenous nerve

Landmark technique

Again, a semicircular subcutaneous infiltration is used, 2 cm above the medial malleolus, injecting 3–5 ml of local anesthetics, on both sides of the great saphenous vein (Fig. 15).

USGB

The probe is placed transversally just proximal and anterior to the medial malleolus, identifying the great saphenous vein (Fig. 16). At this level, saphenous nerve is so small (and already divided in terminal branches) that it can be difficult to clearly visualize and may lie anterior or even posterior to the vein. A perivascular technique can be adopted using local anesthetic injection to identify the nerve

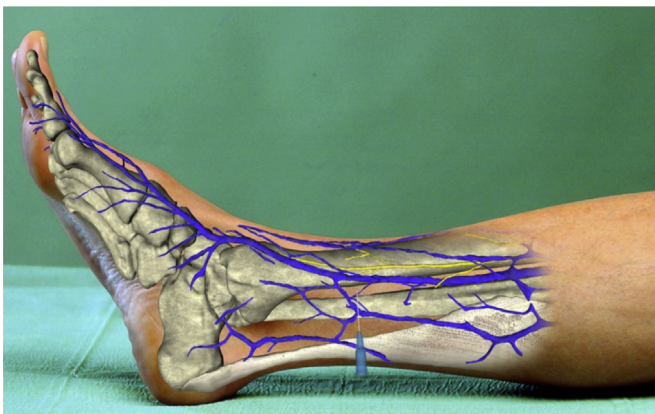


Fig. 15. Saphenous nerve block landmark technique.

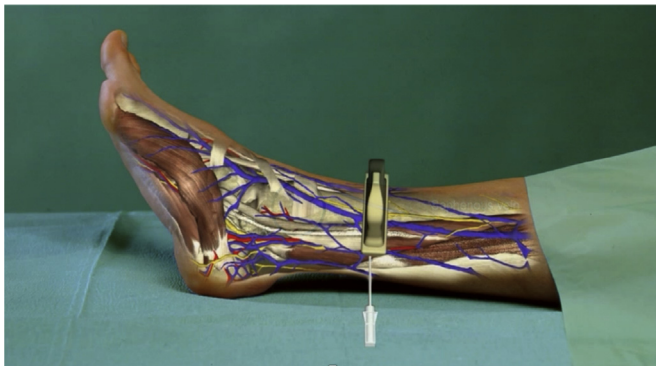


Fig. 16. USGB saphenous nerve block technique.

(Fig. 17). The use of a tourniquet or careful positioning of the leg may help in pinpointing the position of the great saphenous vein.

The decision to perform a saphenous nerve block in addition to a sciatic nerve block or a block to the ankle depends on the planned surgery. Although the saphenous nerve block is mandatory for proximal osteotomy (bifocal osteotomy and Lapidus surgery), it may not be necessary for more distal osteotomies [11].

The onset time after ankle blocks is very rapid and usually only takes a few minutes to work. It does induce very minor motor blockade limited to the plantar interosseous muscles, making walking possible in the immediate postoperative period [7]. However, caution is advised due to loss of proprioception.

Importance of tourniquet position

Foot surgery is often associated with the use of a pneumatic tourniquet, which can be placed at the thigh, calf, or ankle level. The tourniquet position depends on surgical preferences, and on the level of foot surgery. Hindfoot and midfoot surgical procedures are too close to the ankle to use tourniquet at this level. The most suitable indications for ankle blocks will therefore be forefoot surgery because tourniquet can be applied far from the surgical field and can be placed at the ankle level where it is generally very well accepted by the patient (Table 1).

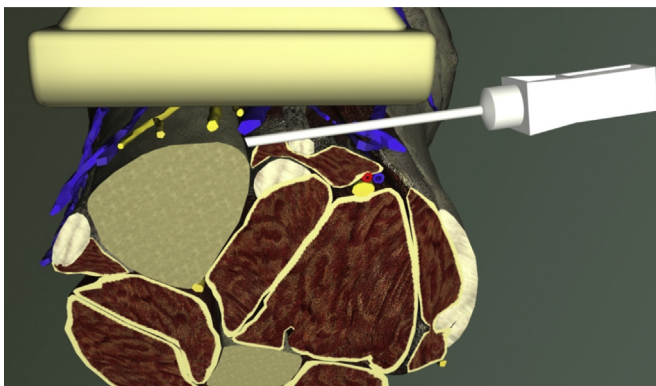
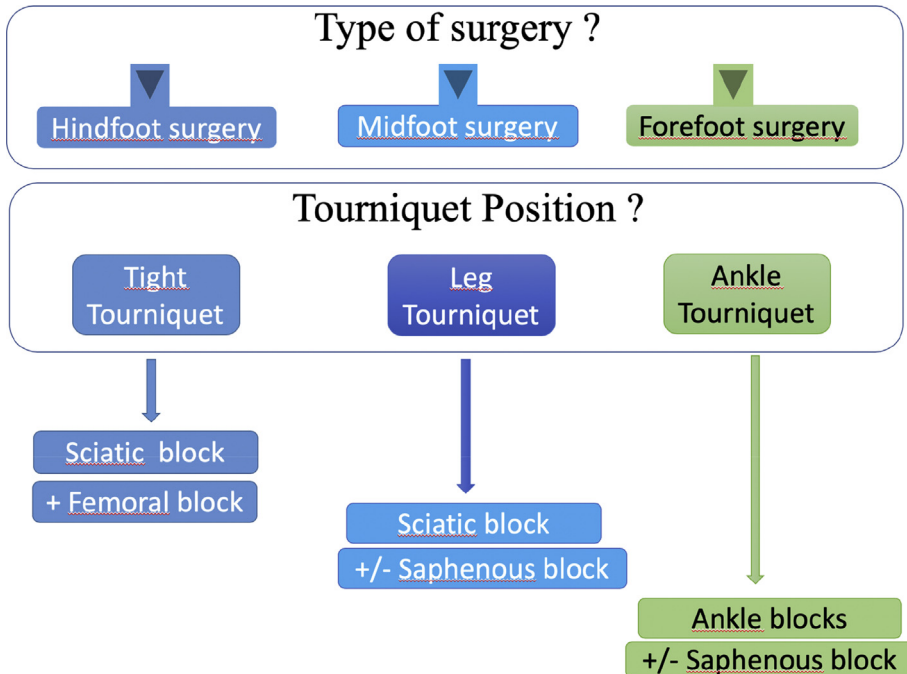


Fig. 17. USGB saphenous nerve block technique.

Table 1

Tourniquet position and advisable nerve blocks.



Combine ankle blocks with another technique of anesthesia

These anesthesia techniques can be used alone or associated with GA and spinal anesthesia (SA) techniques.

Although peripheral nerve block (PNB) is by far the best option to provide superior analgesia for this type surgery, the organizational, technical, and medical expertise constraints can make implementation difficult. GA or SA can be used safely in these circumstances, added with PNB. The ankle blocks will be carried out preoperatively to reduce the level of GA depth and avoid the occurrence of severe postoperative pain immediately after anesthesia awakening.

In anesthesia teams not fully proficient at providing high-quality ankle blocks, surgery can be performed under sciatic block using a short-acting LA (for surgical anesthesia) and a combination of deep peroneal and tibial nerves blocks using long-acting LA (for postoperative analgesia). This combination enables a quick recovery of motor function while providing prolonged postoperative analgesia [26].

Extended postoperative analgesia

Single-shot regional options

As previously mentioned, forefoot surgery is known for intense postoperative pain. To ensure prolonged analgesia, the choice will therefore be on long-acting local anesthetics: bupivacaine, levobupivacaine, or ropivacaine.

USGB allows precise application of local anesthetics close to the nerves while increasing block success chance [7]. This efficacy of USGB also grants the possibility to lower the concentration in a way that lowers neurotoxicity compared to high concentrations (ropivacaine 0.25–0.375%; levobupivacaine 0.25%) [27]. Moreover, the use of diluted LA reduces the risk of systemic toxicity and enables the injection of sufficient volume.

Postoperative pain lasts significantly longer than 24 h. The main strategy must therefore focus on increasing the duration of action of regional blocks through the use of either perineural catheters or adjuvants.

Perineural catheters

A perineural catheter in the popliteal fossa remains one of the gold standards. USGB enables an improved success rate and provides comfortable analgesia by prolonging its duration for 24–48 h [28]. Intermittent LA boli have been replaced by the use of electronic pumps or single-use elastomeric pumps. These latest generation pumps can be used for outpatient care.

A perineural catheter, however, has a number of limitations. First, it is technically much more challenging to perform than a single injection. Second, it is also more expensive. In addition, its use is marred by many technical problems (pressure alarms, leakage, dislocation, etc.) in as high as 30% of all patients receiving catheters [29]. Finally, competent care network is mandatory for optimal outpatient use when adopting catheter techniques.

However elegant these catheters may be, these challenges and difficulties make them poorly suited for routine ambulatory care.

Adjuvants to local anesthetics

The use of adjuvants could prolong analgesia duration of LA after a single injection technique beyond the first 12 h [7].

Perineurally administered dexamethasone is effective in prolonging analgesia even at low doses (1–4 mg) [7,19]. However intravenous injection, at a dosage of 8–10 mg, also ensures effective analgesia [7,30,31]. Because all types of perineural adjuvant are considered as strictly off-label use, the route of administration should be carefully considered in each case.

Dexmedetomidine has also been reported to be effective, prolonging the analgesic duration of PNB. In a study on saphenous nerve blocks at the adductor canal level, the mean duration of sensory block in patients receiving ropivacaine plus dexmedetomidine was 22 h [32]. A dose of 1–2 µg/kg of perineural dexmedetomidine increases the duration of PNB and leads to a dose-dependent sedation and anxiolysis with sympatholytic properties such as hypotension and bradycardia [33]. The use of dexmedetomidine also increases the cost of care in a quite significant way. According to some studies, both perineural and IV dexmedetomidine can effectively prolong PNB duration [34,35].

Conclusion

The development of USGB has enabled us to perform very selective and precise nerve blocks. Even small sensory end nerves, at the ankle level, can easily be identified and blocked using very low dose and concentration of local anesthetics. This modern era practice leads to rapid patient mobility and discharge.

The choice of the RA technique will depend heavily on the type of surgery, the position of the tourniquet, and the experience in regional techniques of the anesthesia team. The current evolution toward ambulatory care will push surgical teams to favor techniques that simplify postoperative treatment and encourage immediate ambulation. Sciatic popliteal catheters for ambulatory surgery require complex care and should only be reserved for specific cases.

Ankle blocks provide excellent intraoperative anesthesia as well as long postoperative pain relief. Both perineural and systemic routes of dexamethasone provide comparable postoperative analgesia, thereby reducing total opioid consumption [7].

Revival of ankle blocks is a perfect example of the high impact of new technological advances in improving ambulatory surgical care after foot surgery.

Practice points

- Ultrasound-guided ankle blocks are a reliable way to achieve analgesia and anesthesia of the foot while maintaining motor function and enabling fast mobilization.
- Ultrasound-guided ankle blocks have a higher chance of success rate than the blind technique.
- The deep peroneal and tibial nerves are mandatory for foot surgery because they innervate the bony structures.
- The superficial peroneal, sural, and saphenous nerves provide mostly sensory input and require only a low dose of local anesthetics.
- Addition of dexamethasone IV to prolong ankle blocks can significantly enhance the duration of analgesic effect.
- When the use of tourniquet is desired, GA, SA, or sciatic/high saphenous/femoral addition to the ankle block can be considered.

Research points

- More studies comparing popliteal block versus ankle blocks in ambulatory settings are needed.
- There is need to conduct economic impact studies on popliteal catheters in ambulatory settings versus ankle blocks and dexamethasone.
- More research on IV versus perineural adjuvants in small sensory nerves is required.
- Fast ambulation and long-term functional outcome research after ankle blocks could prove to be fascinating.
- Liposomal bupivacaine to prolong ankle blocks and provide pain relief beyond 24 h could add a new dimension in the search for perfect analgesia in painful foot surgery

Disclosures

Alain Delbos, MD: No conflict of interest.

Marty Philippe, MD: No conflict of interest.

Chassery Clément, MD: No conflict of interest.

Rontes Olivier, MD: No conflict of interest.

Steve Coppens, MD: Dr Coppens has received funding from BK MEDICAL as an instructor of ultrasound workshops and from MSD for lectures and courses on ERAS in colorectal surgery.

References

- [1] Stefani KC, Ferreira GF, Pereira Filho MV. Postoperative analgesia using peripheral anesthetic block of the foot and ankle. *Foot Ankle Int* 2018;39:196–200.
- [2] Chaudier P, Bourdin M, Gauthier J, et al. Similar levels of pain are reported in forefoot surgery after management as a day case and admission for 48 hours: a continuous prospective study of 317 patients. *Bone Joint J* 2015;97-B:1645–50.
- [3] Mouton A, Le Strat V, Medevielle D, et al. Patient's satisfaction after outpatient forefoot surgery: study of 619 cases. *Orthop Traumatol Surg Res* 2015;101:S217–20.
- [4] Merrill HM, Dean DM, Mottla JL, et al. Opioid consumption following foot and ankle surgery. *Foot Ankle Int* 2018;39:649–56.

- [5] White PF, Issioui T, Skrivaneck GD, et al. The use of a continuous popliteal sciatic nerve block after surgery involving the foot and ankle: does it improve the quality of recovery? *Anesth Analg* 2003;97:1303–9.
- [6] Rudkin GE, Rudkin AK, Dracopoulos GC Ankle block success rate: a prospective analysis of 1,000 patients. *Can J Anaesth* 2005;52:209–10.
- *[7] Marty P, Rontes O, Chassery C, et al. Perineural versus systemic dexamethasone in front-foot surgery under ankle block: a randomized double-blind study. *Reg Anesth Pain Med* 2018;43:732–7.
- *[8] Kahn RL, Ellis SJ, Cheng J, et al. The incidence of complications is low following foot and ankle surgery for which peripheral nerve blocks are used for postoperative pain management. *HSS J* 2018;14:134–42.
- [9] Park YU, Cho JH, Lee DH, et al. Complications after multiple-site peripheral nerve blocks for foot and ankle surgery compared with popliteal sciatic nerve block Alone. *Foot Ankle Int* 2018;39:731–5.
- [10] Delbos. *Peripheral nerve blocks on DVD version 3- lower limbs*. Philadelphia: Lippincott; 2012.
- *[11] López AM, Sala-Blanch X, Magaldi M, et al. Ultrasound-guided ankle block for forefoot surgery: the contribution of the saphenous nerve. *Reg Anesth Pain Med* 2012;37:554–7.
- [12] Mazzella NL, McMillan AM. Contribution of the sural nerve to postural stability and cutaneous sensation of the lower limb. *Foot Ankle Int* 2015;36:450–6.
- [13] Provenzano DA, Viscusi ER, Adams Jr SB, et al. Safety and efficacy of the popliteal fossa nerve block when utilized for foot and ankle surgery. *Foot Ankle Int* 2002;23:394–9.
- *[14] Perlas A, Brull R, Chan VW, et al. Ultrasound guidance improves the success of sciatic nerve block at the popliteal fossa. *Reg Anesth Pain Med* 2008;33:259–65.
- *[15] Karmakar MK, Shariat AN, Pangthipampai P, et al. High-definition ultrasound imaging defines the paraneural sheath and the fascial compartments surrounding the sciatic nerve at the popliteal fossa. *Reg Anesth Pain Med* 2013;38:447–51.
- [16] Karmakar M, Li X, Li J, et al. Three-dimensional/four-dimensional volumetric ultrasound imaging of the sciatic nerve. *Reg Anesth Pain Med* 2012;37:60–6.
- *[17] Choquet O, Noble GB, Abbal B, et al. Subparaneural versus circumferential extraneural injection at the bifurcation level in ultrasound-guided popliteal sciatic nerve blocks: a prospective, randomized, double-blind study. *Reg Anesth Pain Med* 2014;39:306–11.
- *[18] Chin KJ, Wong NW, Macfarlane AJ, et al. Ultrasound-guided versus anatomic landmark-guided ankle blocks: a 6-year retrospective review. *Reg Anesth Pain Med* 2011;36:611–8.
- [19] Lawson IR, Ingman SR, Masih Y, et al. Reliability of palpation of pedal pulses as ascertained by the kappa statistic. *J Am Geriatr Soc* 1980;28:300–3.
- [20] Doty Jr R, Sukhani R, Kendall MC, et al. Evaluation of a proximal block site and the use of nerve-stimulator-guided needle placement for posterior tibial nerve block. *Anesth Analg* 2006;103:1300–5.
- [21] Antonakakis JG, Scalzo DC, Jorgenson AS, et al. Ultrasound does not improve the success rate of a deep peroneal nerve block at the ankle. *Reg Anesth Pain Med* 2010;35:217–21.
- [22] Benzon HT, Sekhadia M, Benzon HA, et al. Ultrasound-assisted and evoked motor response stimulation of the deep peroneal nerve. *Anesth Analg* 2009;109:2022–4.
- [23] Mowlavi A, Whiteman J, Wilhelm BJ, et al. Dorsalis pedis arterial pulse: palpation using a bony landmark. *Postgrad Med J* 2002;78:746–7.
- [24] Prakash I, Bhardwaj AK, Singh DK, et al. Anatomic variations of superficial peroneal nerve: clinical implications of a cadaver study. *Ital J Anat Embryol* 2010;115:223–8.
- [25] Bowness J, Turnbull K, Taylor A, et al. Identifying the emergence of the superficial peroneal nerve through deep fascia on ultrasound and by dissection: implications for regional anaesthesia in foot and ankle surgery. *Clin Anat* 2018.
- [26] Redborg KE, Sites BD, Chinn CD, et al. Ultrasound improves the success rate of a sural nerve block at the ankle. *Reg Anesth Pain Med* 2009;34:24–8.
- [27] Samuel R, Sloan A, Patel K, et al. The efficacy of combined popliteal and ankle blocks in forefoot surgery. *J Bone Joint Surg Am* 2008;90:1443–6.
- [28] Taha AM, Abd-Elmaksoud AM. Ropivacaine in ultrasound-guided femoral nerve block: what is the minimal effective anaesthetic concentration (EC90)? *Anaesthesia* 2014;69:678–82.
- *[29] Bendtsen TF, Nielsen TD, Rohde CV, et al. Ultrasound guidance improves a continuous popliteal sciatic nerve block when compared with nerve stimulation. *Reg Anesth Pain Med* 2011;36:181–4.
- [30] Dadure C, Capdevila X. Peripheral catheter techniques. *Paediatr Anaesth* 2012;22:93–101.
- [31] Fredrickson Fanzca MJ, Danesh-Clough TK, White R. Adjuvant dexamethasone for bupivacaine sciatic and ankle blocks: results from 2 randomized placebo-controlled trials. *Reg Anesth Pain Med* 2013;38:300–7.
- *[32] Desmet M, Braems H, Reynvoet M, et al. I.V. and perineural dexamethasone are equivalent in increasing the analgesic duration of a single-shot interscalene block with ropivacaine for shoulder surgery: a prospective, randomized, placebo-controlled study. *Br J Anaesth* 2013;111:445–52.
- [33] Andersen JH, Grevstad U, Siegel H, et al. Does dexmedetomidine have a perineural mechanism of action when used as an adjuvant to ropivacaine?: a paired, blinded, randomized trial in healthy volunteers. *Anesthesiology* 2017;126:66–73.
- [34] Hussain N, Grzywacz VP, Ferreri CA, et al. Investigating the efficacy of dexmedetomidine as an adjuvant to local anesthesia in brachial plexus block: a systematic review and meta-analysis of 18 randomized controlled trials. *Reg Anesth Pain Med* 2017;42:184–96.
- *[35] Abdallah FW, Dwyer T, Chan VW, et al. IV and perineural dexmedetomidine similarly prolong the duration of analgesia after interscalene brachial plexus block: a randomized, three-arm, triple-masked, placebo-controlled trial. *Anesthesiology* 2016;124:683–95.